

# The Heart

Nicole Storer, RN  
Jerry Smedley DO

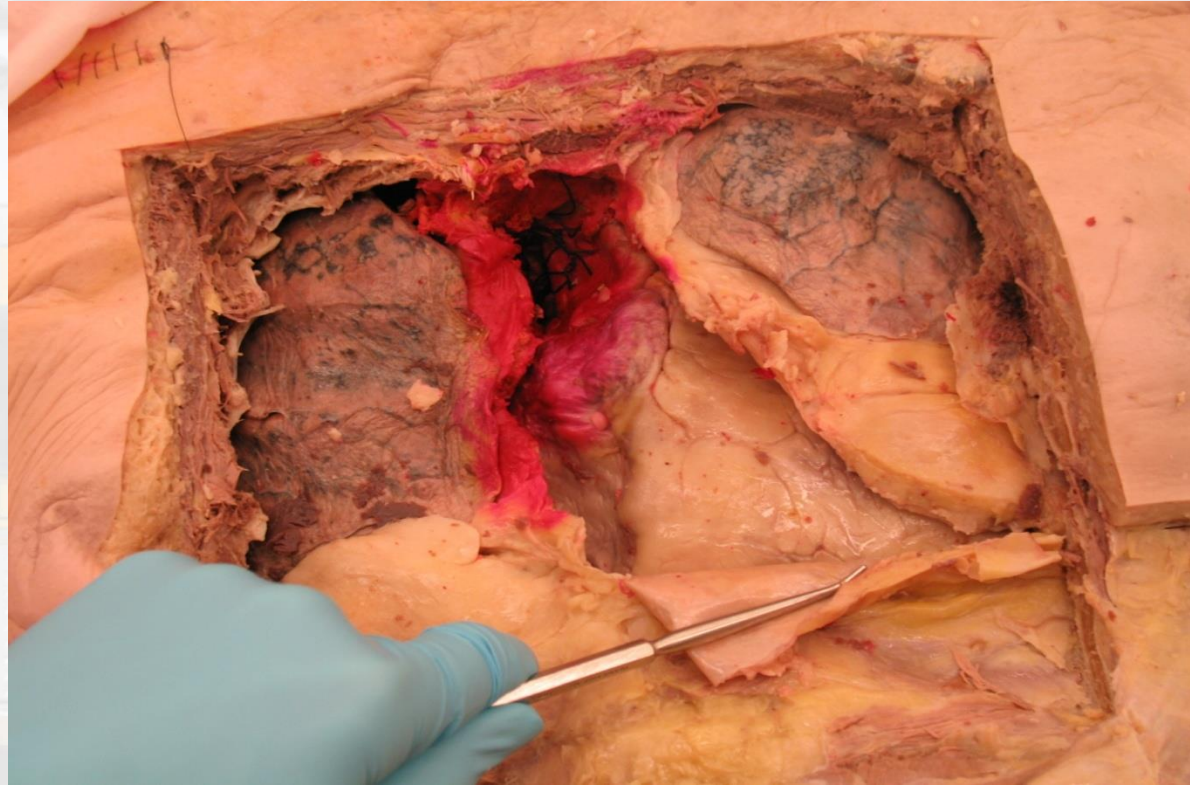
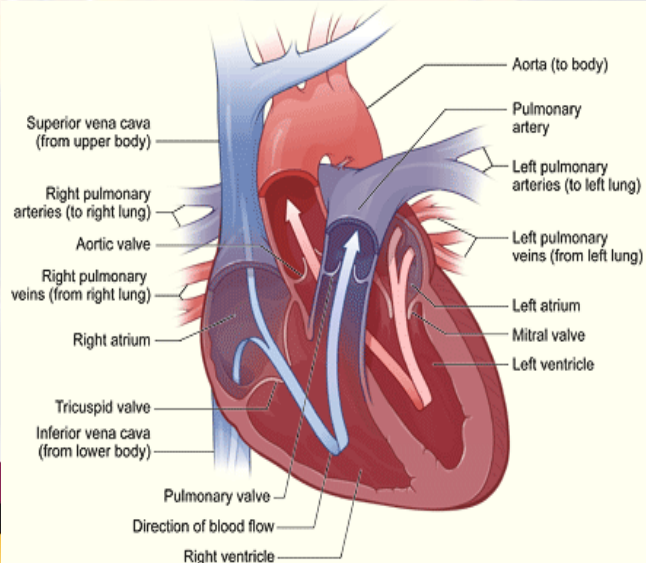


# Objectives

- Understand the anatomy of the heart especially blood flow to major areas of heart muscle
- Learn basic EKG analysis
- Anatomically link infarcts with EKG findings

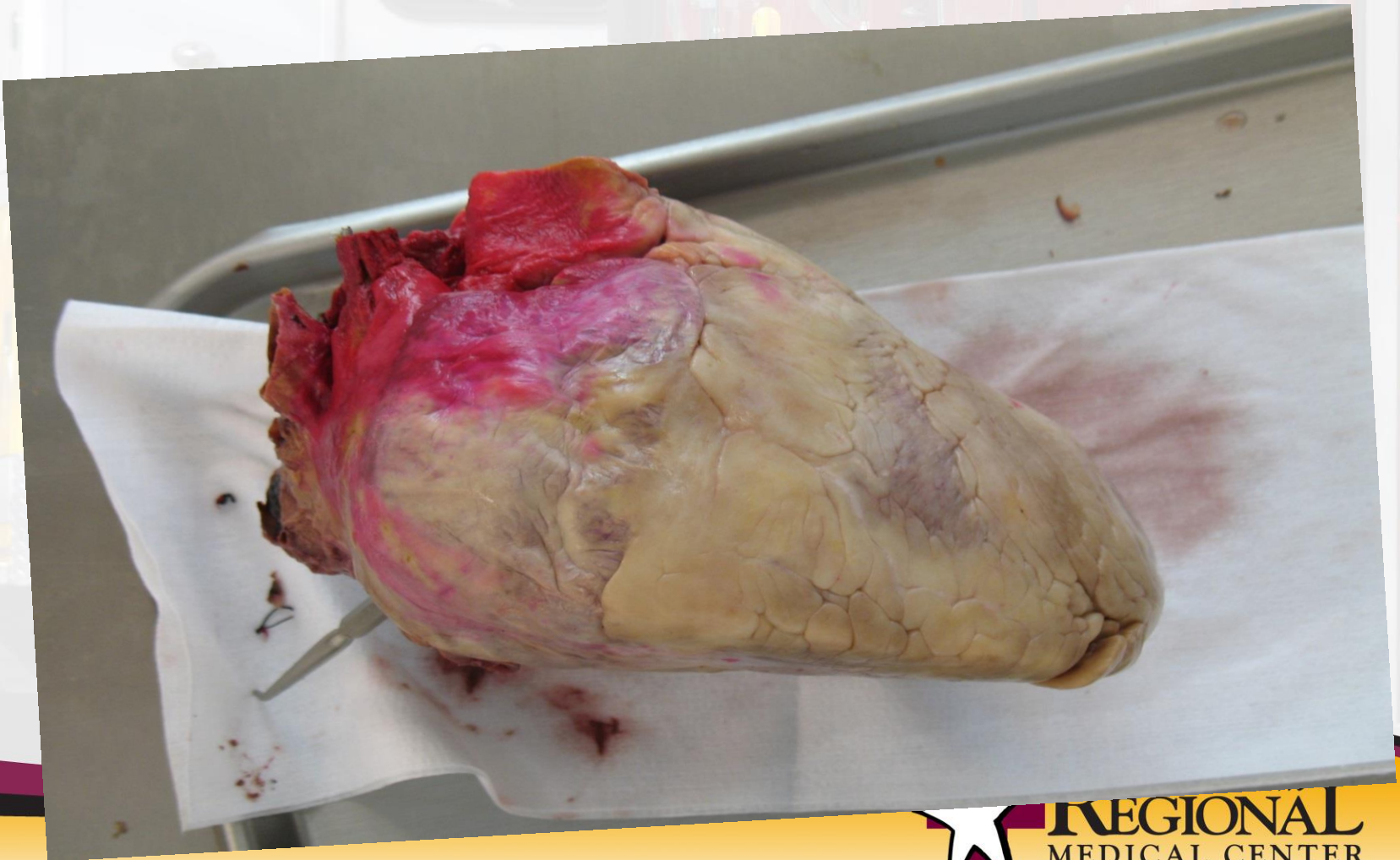# Anatomy: The Heart

- In the mediastinum
- Surrounded by pericardium
- 4 chambers
- Connects the great vessels
- Supplies the body with oxygenated blood





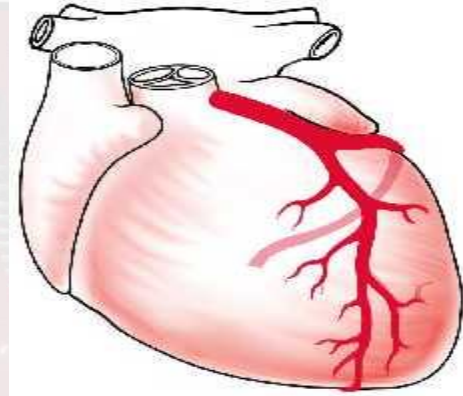
# What Supplies the Heart With Blood?



# Blood supply to the heart

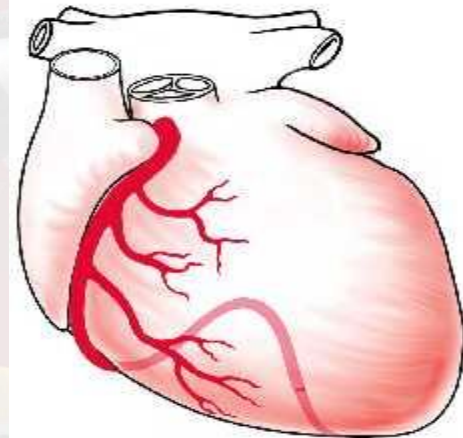
## Left Coronary

- Circumflex artery
- Left anterior descending artery



## Right Coronary

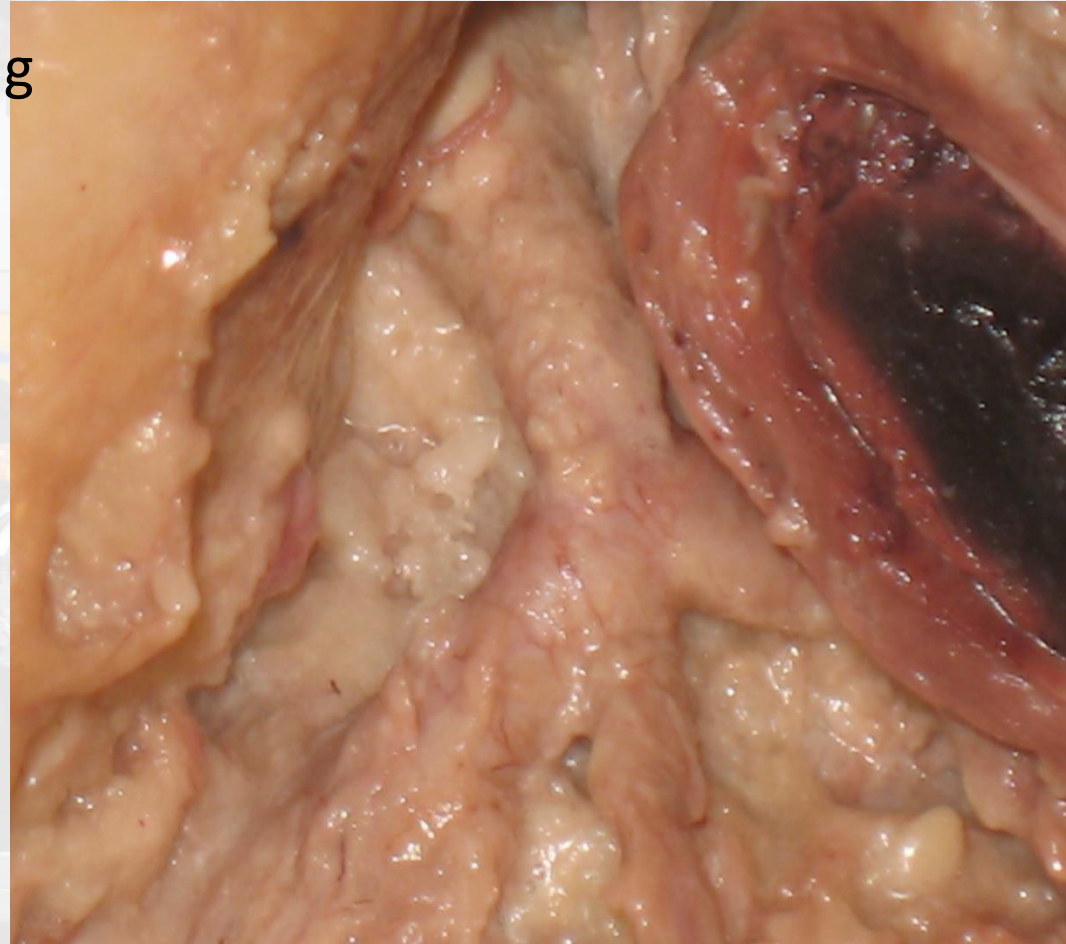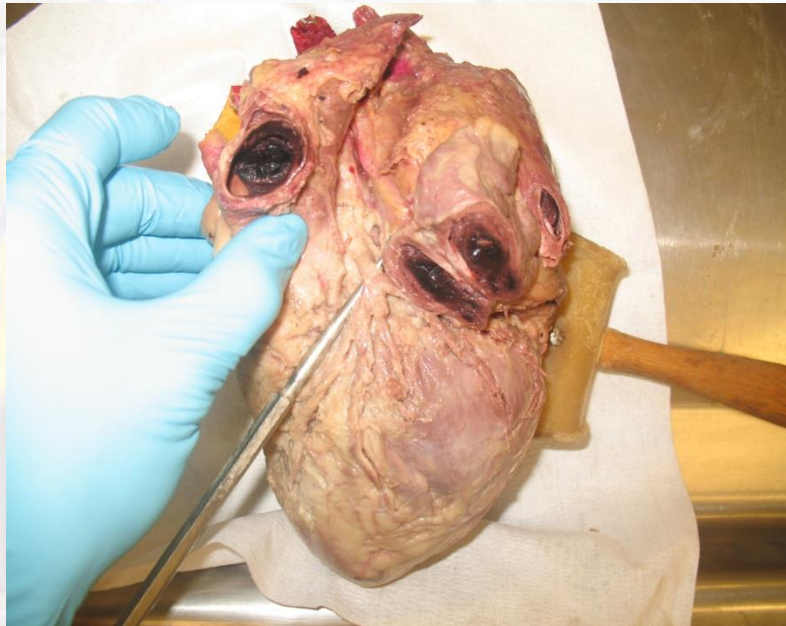
- Right marginal artery
- Posterior descending artery



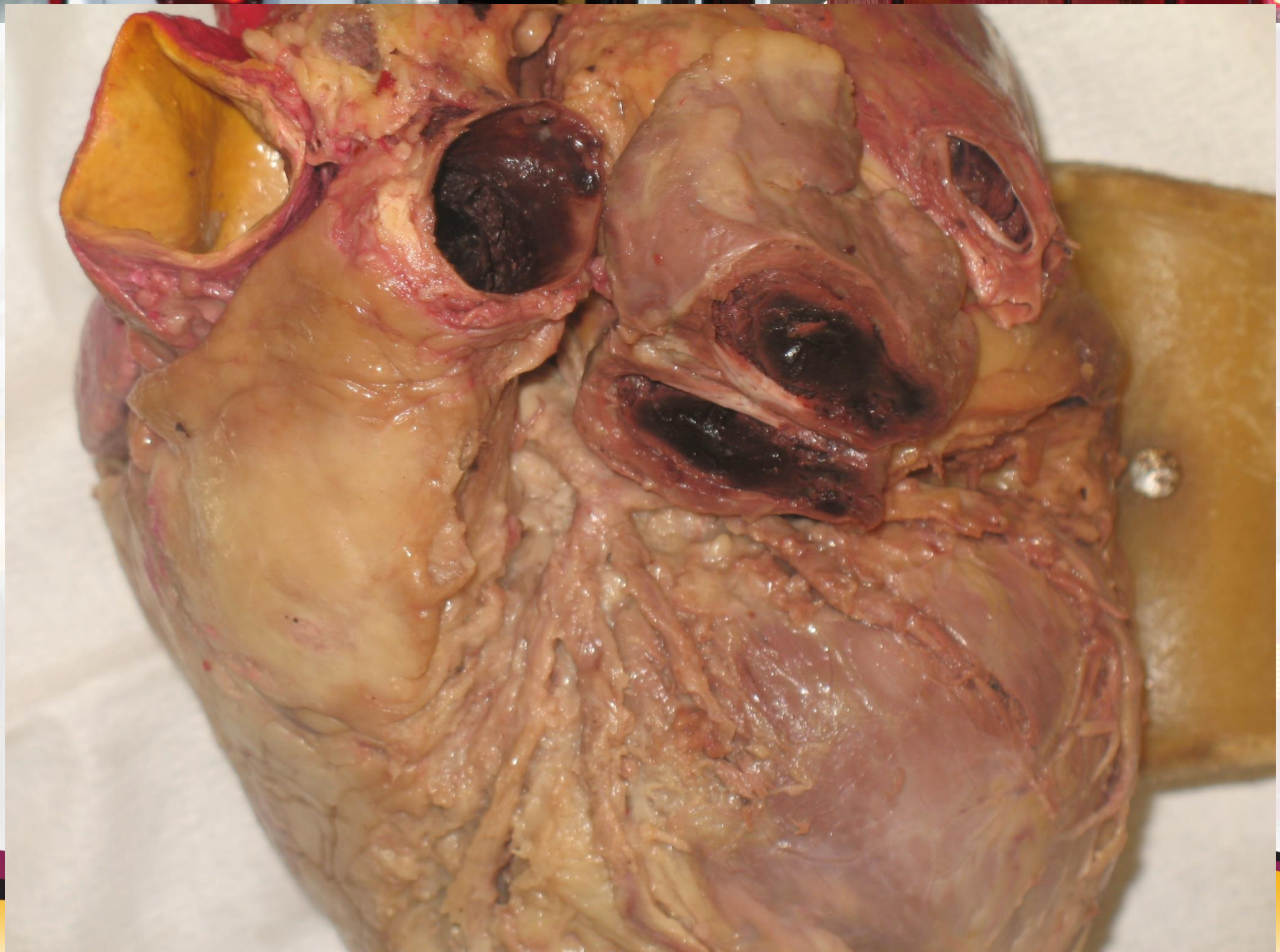

# Left Coronary

- Circumflex artery
- Left anterior descending artery

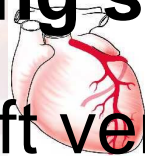





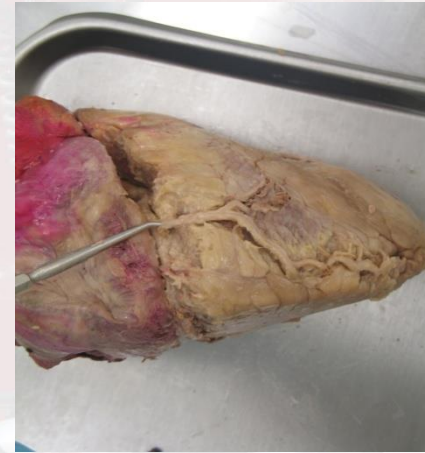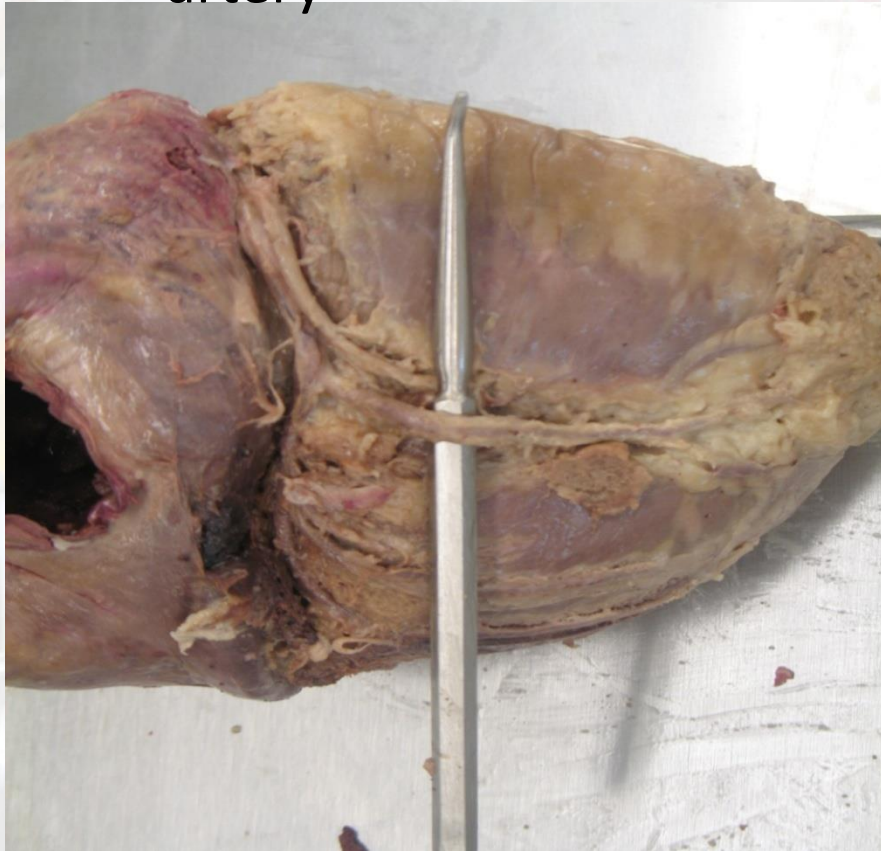
# Left Coronary

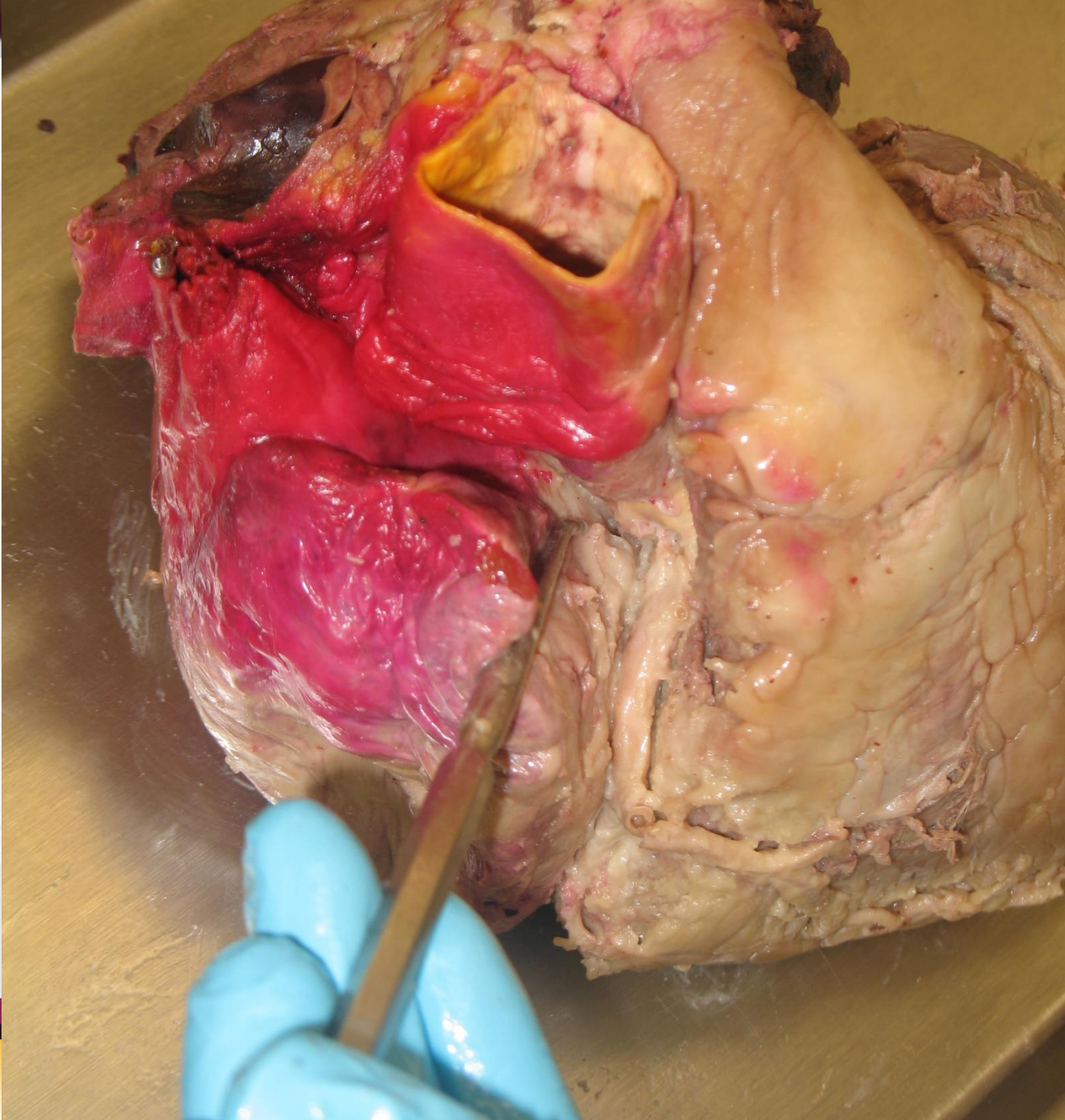
- **Circumflex supplies:**  
left atrium, the side & back of the left ventricle
- **Left anterior descending supplies:**  
front & bottom of the left ventricle & the front of the septum





- Right Coronary
  - Right marginal artery
  - Posterior descending artery

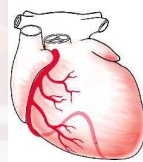






# Right Coronary

- right atrium
- right ventricle
- bottom (inferior) portion of both ventricles and back of the septum



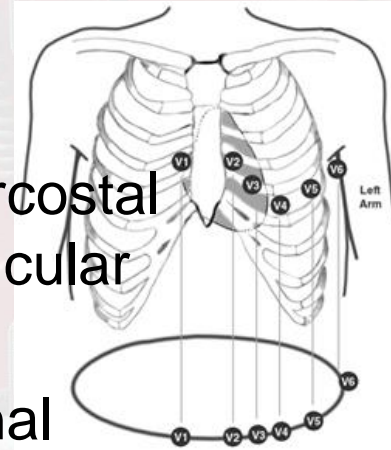
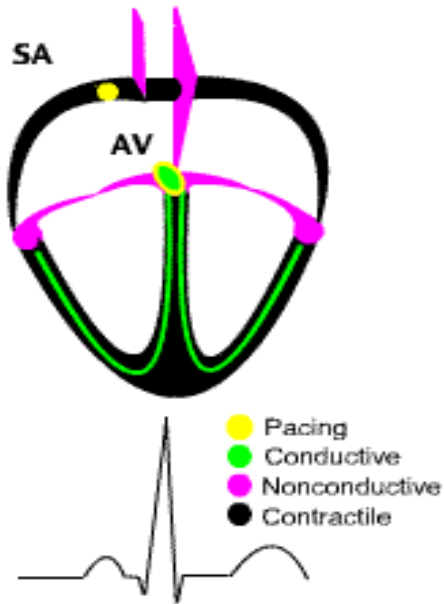
**How can we tell how the heart is functioning?**

**EKG's!**



# EKG's: What you need to know

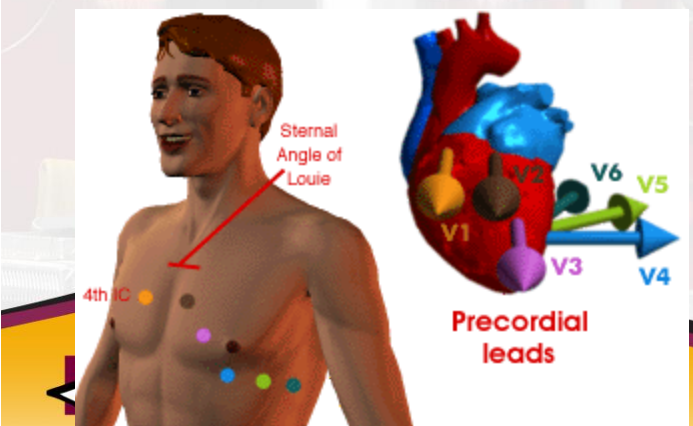
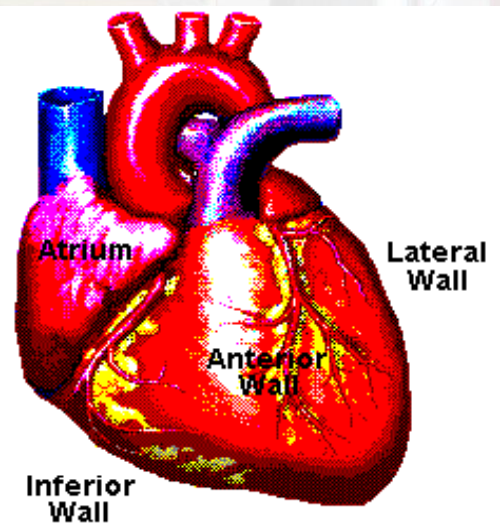
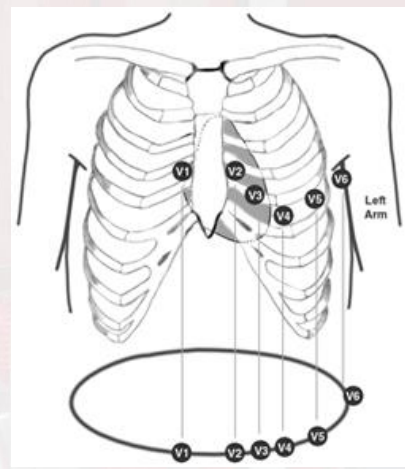
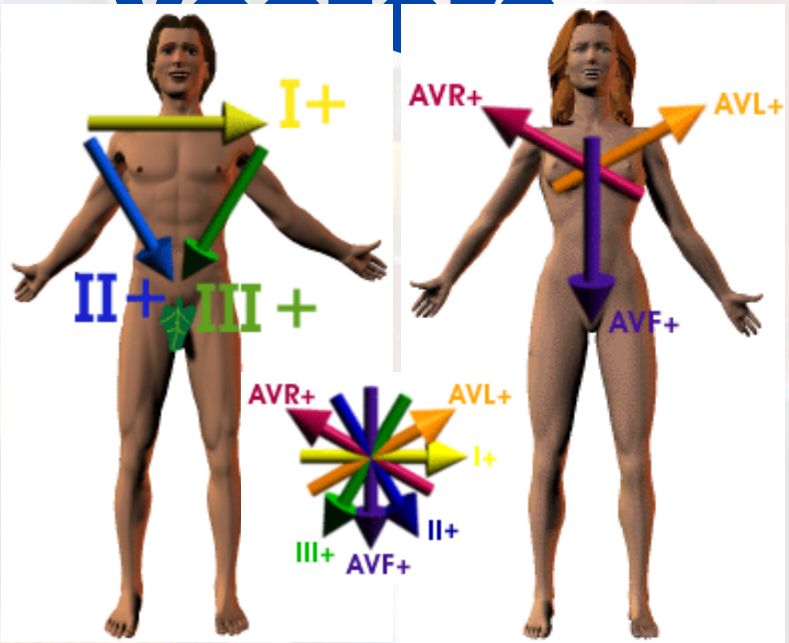
- V1 and V2 lie lateral to the sternum in the 4<sup>th</sup> intercostal space.
- V4 lies in the 5<sup>th</sup> intercostal space in the midclavicular line.
- V3 lies on the diagonal between V2 and V4
- V5 lies in the 5<sup>th</sup> intercostal space on the axillary line.
- V6 lies in the 5<sup>th</sup> intercostal space on the mid axillary line.



# Limb and Precordial Leads:

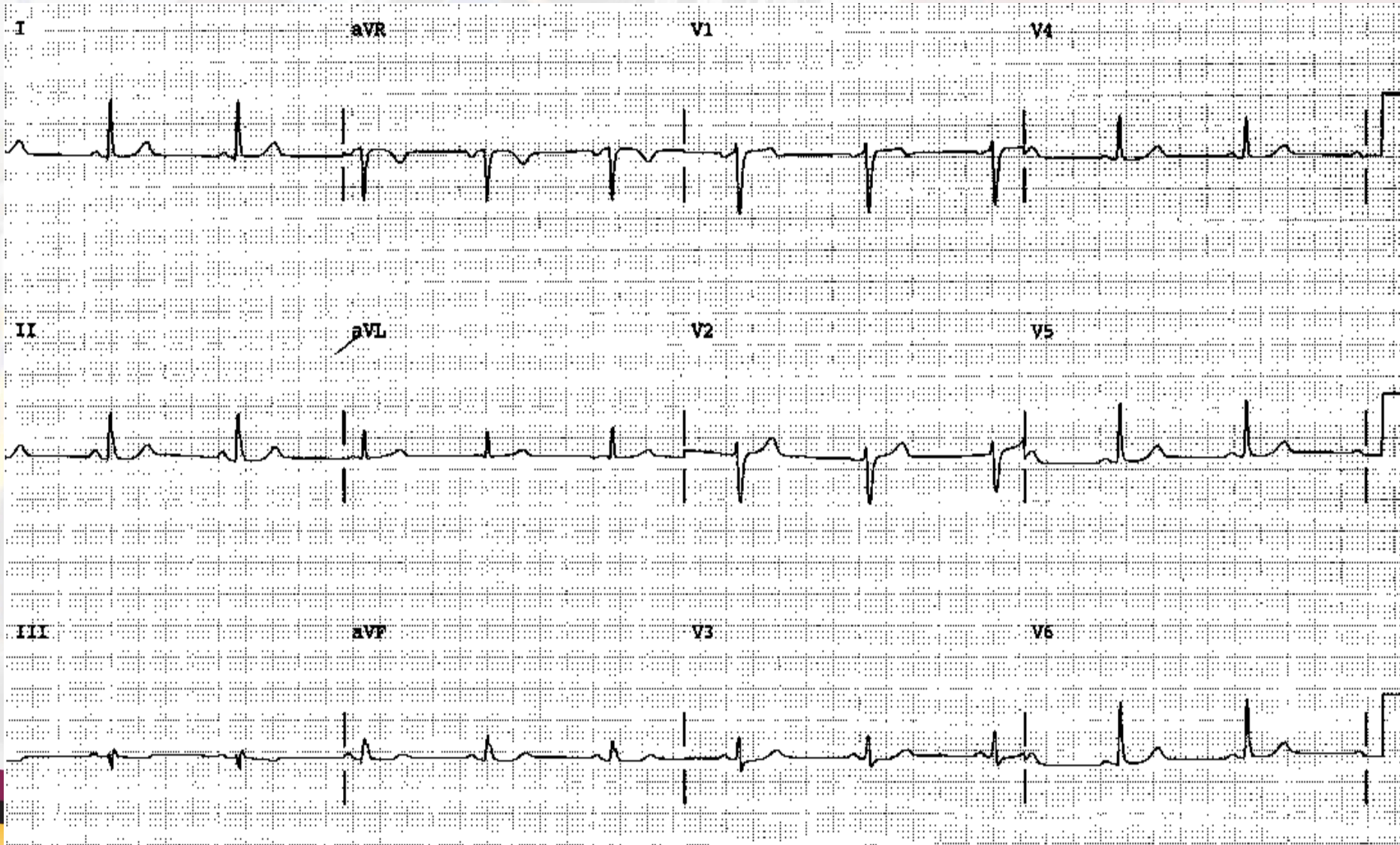
## Vector

- **Inferior Wall:**
  - LII, LIII, aVF
- **Septal Wall:**
  - V1, V2
- **Anterior Wall:**
  - V3, V4
- **Lateral Wall:**
  - V5, V6, LI, aVL
- **Posterior Wall:**
  - V1, V2





# Normal EKG



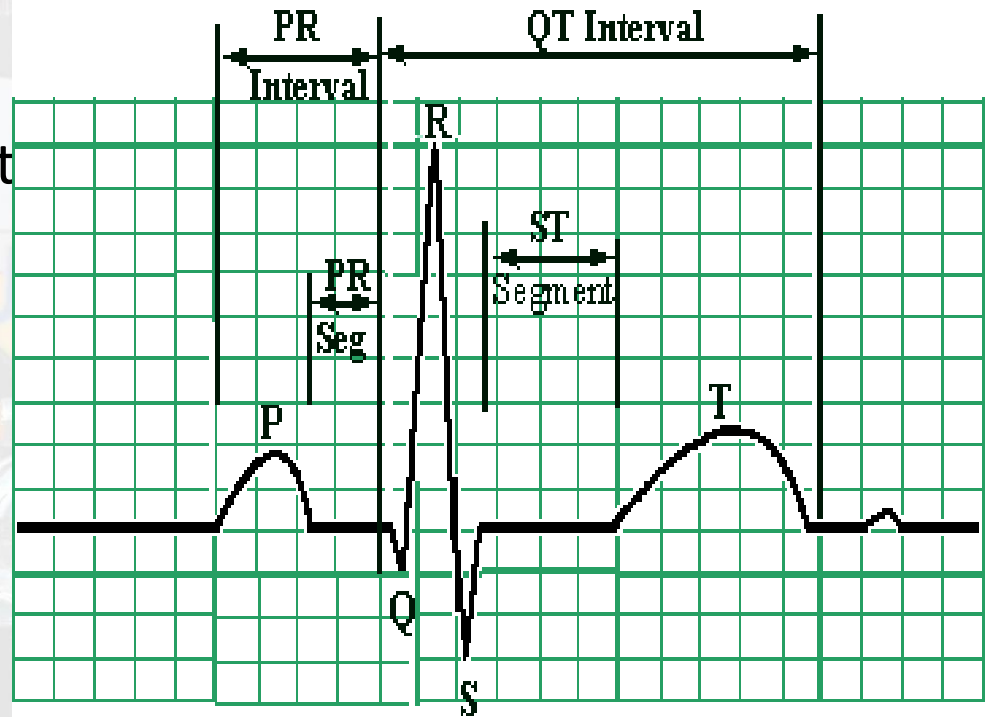
# Lead Patterns

I Lateral	aVR	V1 Septal	V4 Anterior
II Inferior	aVL Lateral	V2 Septal	V5 Lateral
III Inferior	aVF Inferior	V3 Anterior	V6 Lateral




# EKG Waves

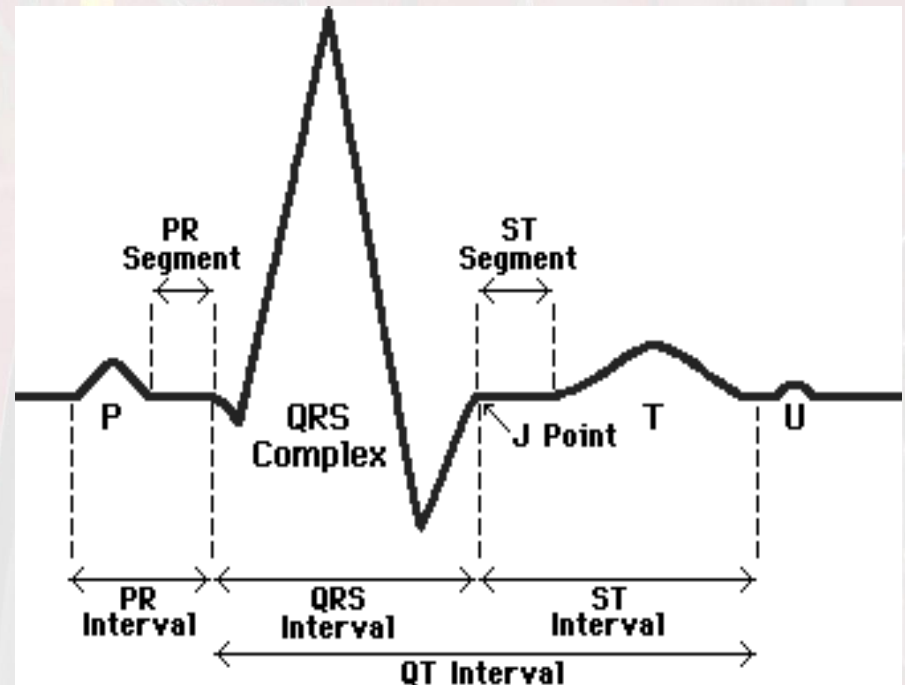
- P wave
  - Depolarization of the atria
- QRS Complex
  - Depolarization of the ventricle
- T wave
  - Repolarization of the ventricle



# What you need to know cont.



- normal PR interval
  - 0.12 to 0.20 s (3 - 5 small squares)
- normal QRS complex
  - < 0.12 s duration (3 small squares)
- normal QT interval
  - Normal = 0.42 s.
- **normal ST segment**
  - no elevation or depression
- Normal T wave
  - Upright



The PR interval, QRS complex, and the QT interval signify the duration of contraction of atria and ventricle.



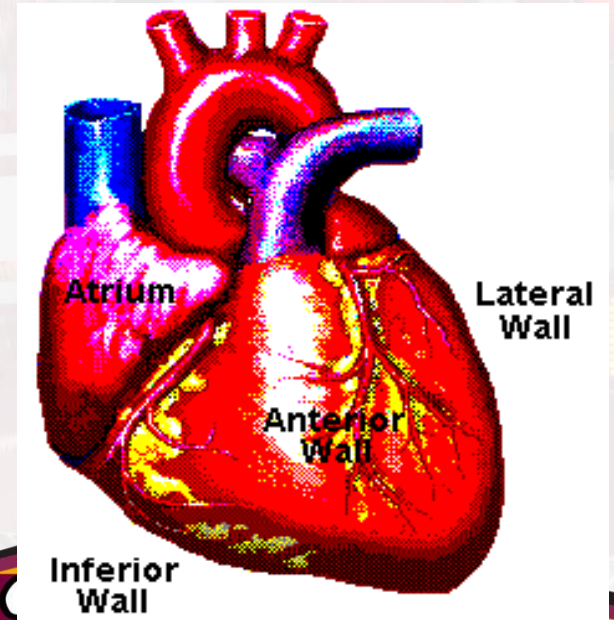
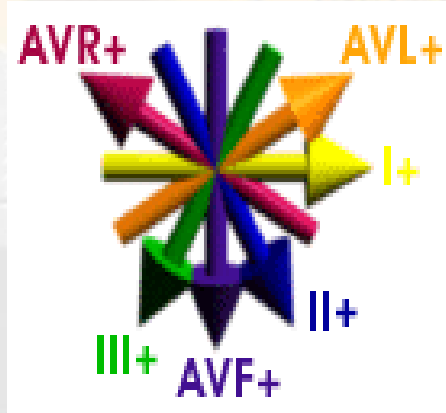
Eastern Idaho  
**REGIONAL**  
MEDICAL CENTER



# What abnormalities exist?

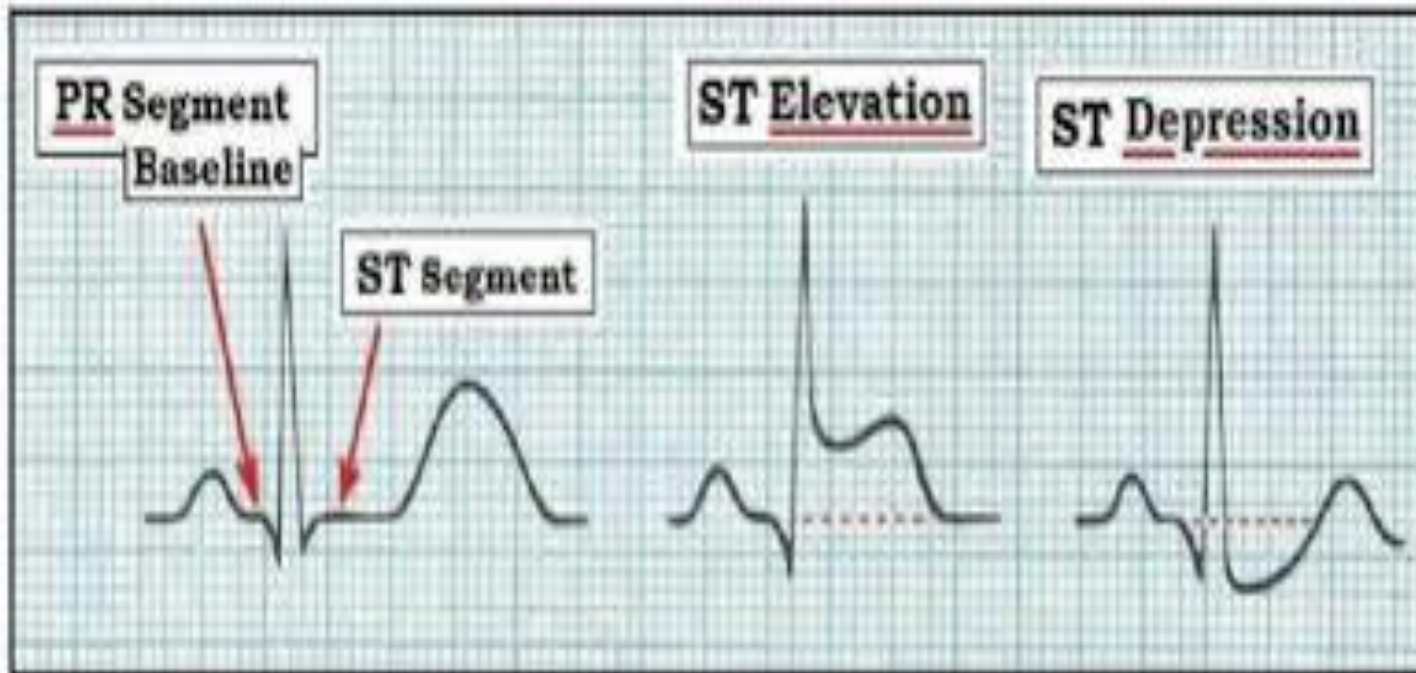
- Common abnormalities
  - Infarcts
    - Anterior, Posterior, Lateral, Septal, Inferior,
  - Right and Left BBB's
  - Right and Left Ventricular Hypertrophy
  - Left Anterior and Posterior Fascicular Blocks
  - Right and Left Atrial enlargements
  - Right and Left Axis deviation

**Infarcts- What do infarcts look like on an EKG? Where are the occlusions that cause them? How will you locate them both on the EKG?**





# Infarcts on an EKG: ST depression and elevation

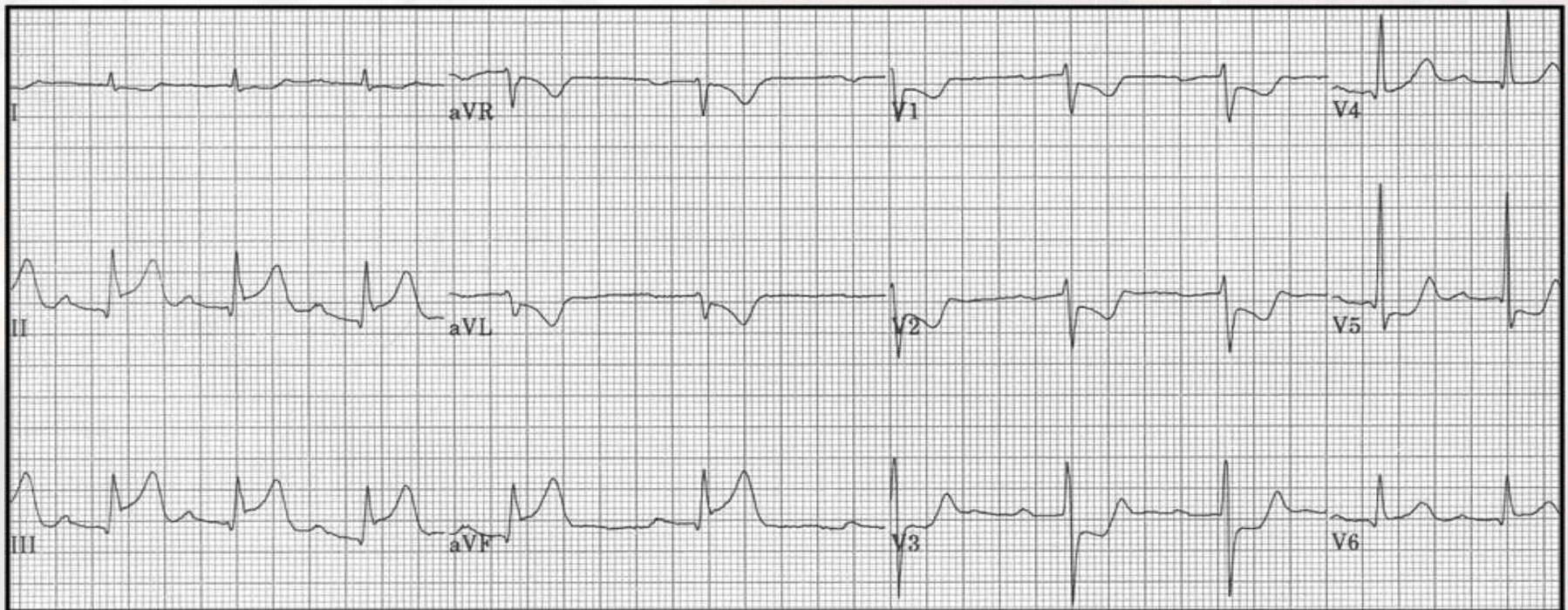


## Inferior Infarct

ST elevation is seen in leads II, III, and F.

The inferior portion of the heart is supplied by the right coronary artery in most persons, but can also be serviced by the left circumflex artery.

**Occlusion of a dominant right coronary artery produces inferior infarction.**

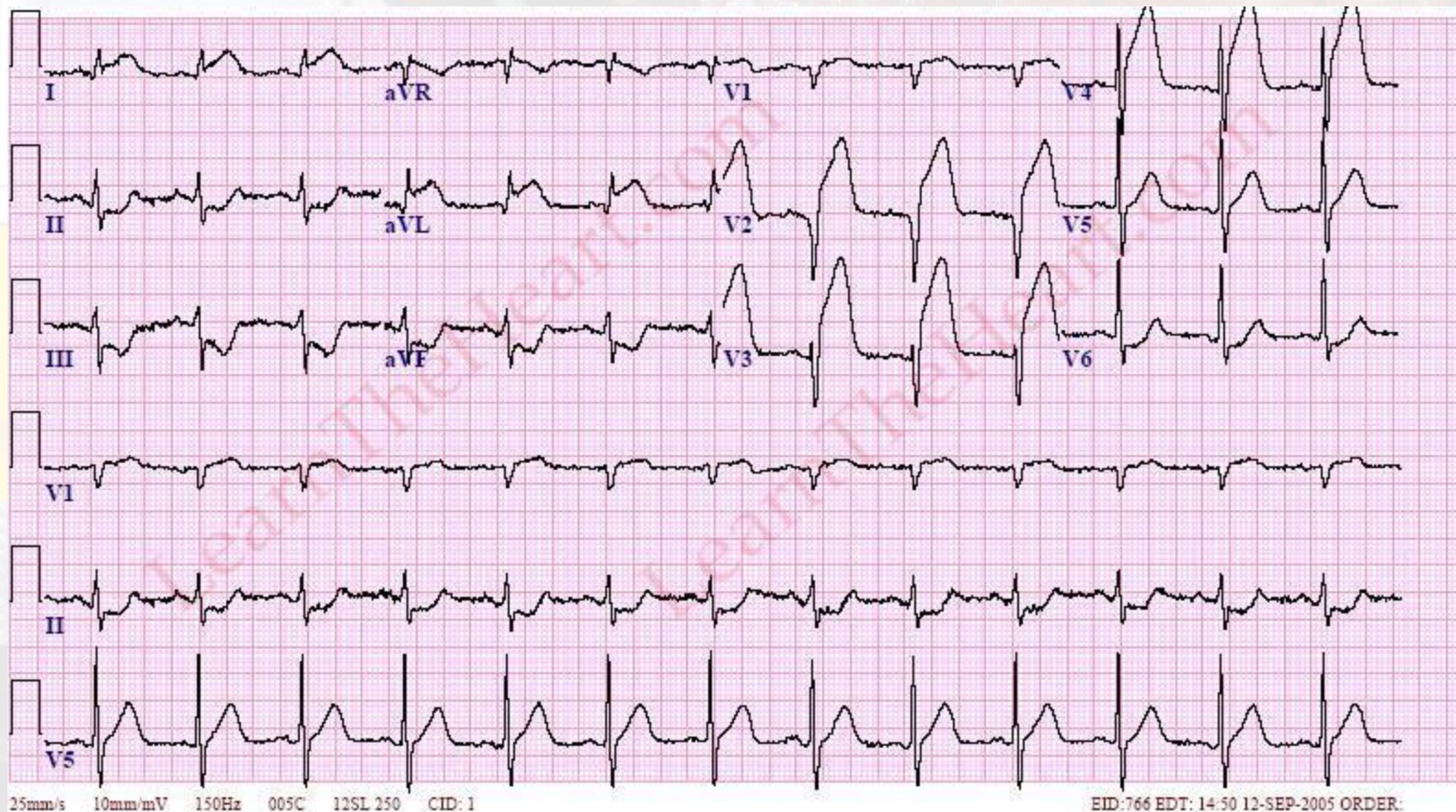




# Anterior Infarct

Signs of infarction will usually be seen in lead I and V2-V4, and often in V1.

Infarction of the anterior wall is caused by occlusion of the left anterior descending coronary artery.

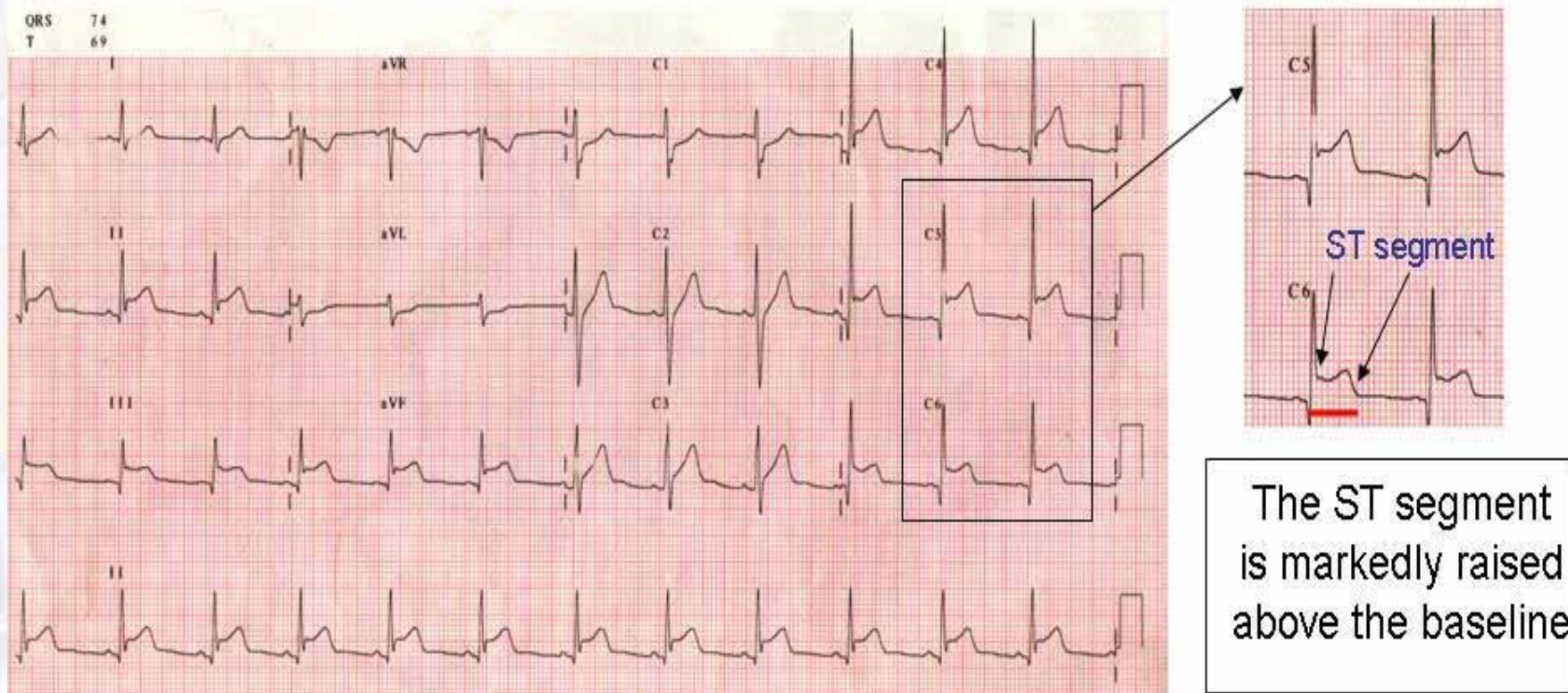




## Lateral Infarct

ST elevations are seen in L and V5-V6. (can also be seen in I)

Lateral wall infarction can result from occlusion of the left circumflex coronary artery, or from a lateral branch of the left anterior descending artery.

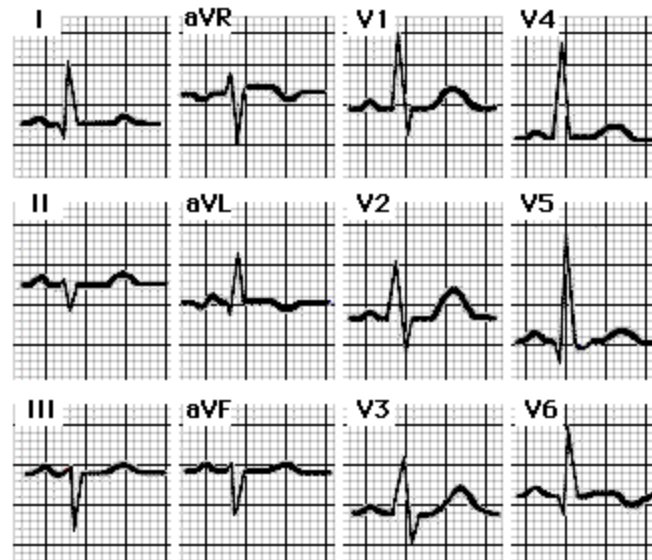
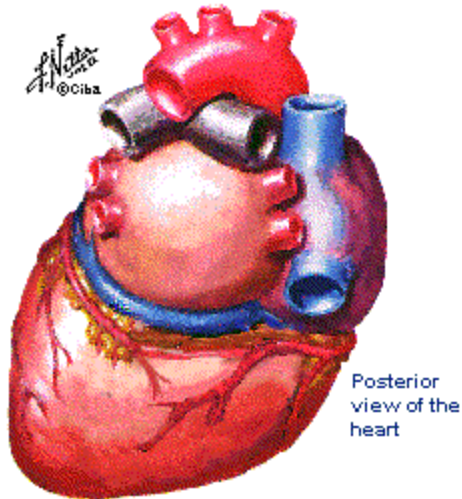


**Posterior Infarct:** Occlusion of the right coronary artery may also produce posterior infarction — with or without inferior infarction. True posterior infarction may produce changes only in lead V1 and V2. The ECG changes of posterior infarction are

**“reciprocal” changes.**

### Localization of Myocardial Infarcts

#### True Posterior Infarct





51 yr old male w/ no prior cardiac hx presents w/ mid-sternal chest discomfort.

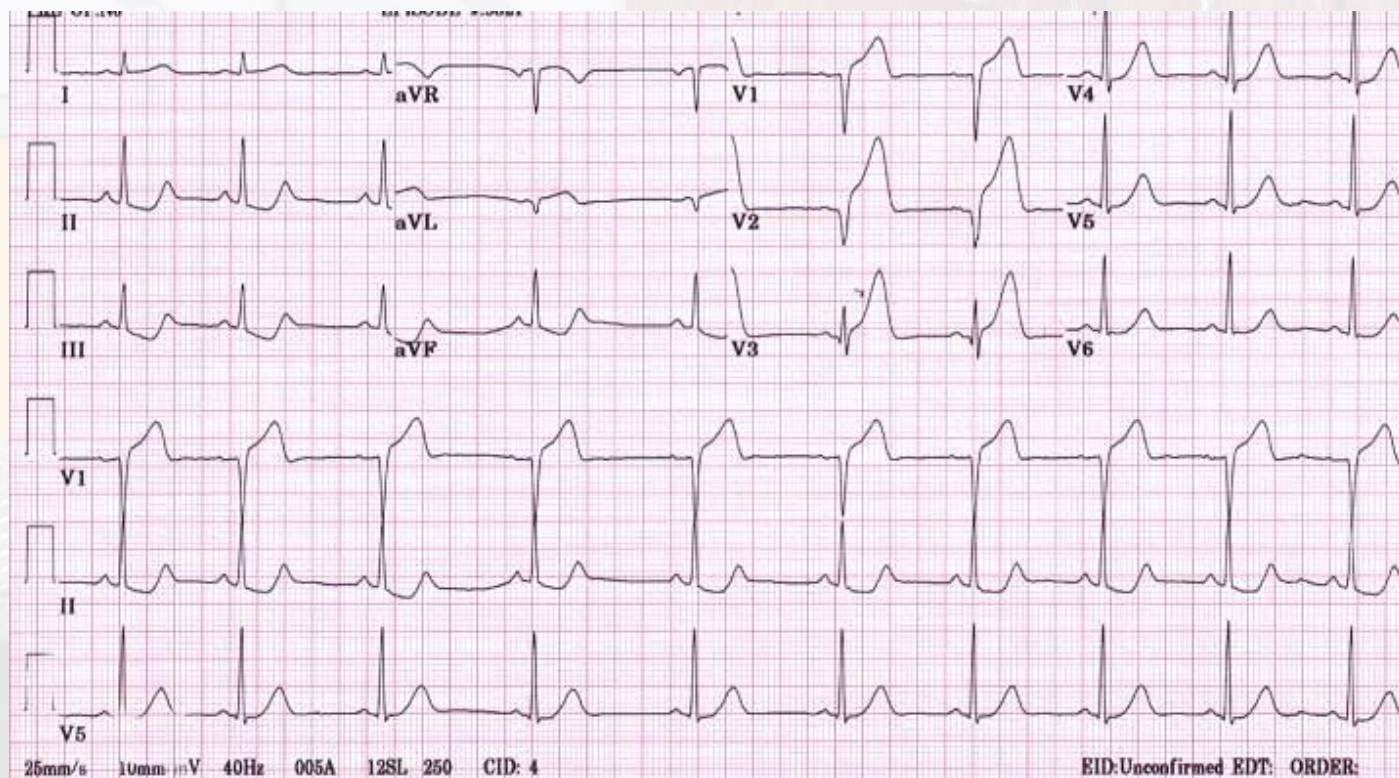
Vent. rate 58 bpm

PR interval 152ms

QSR duration 88ms

QT/QTc 426/418ms

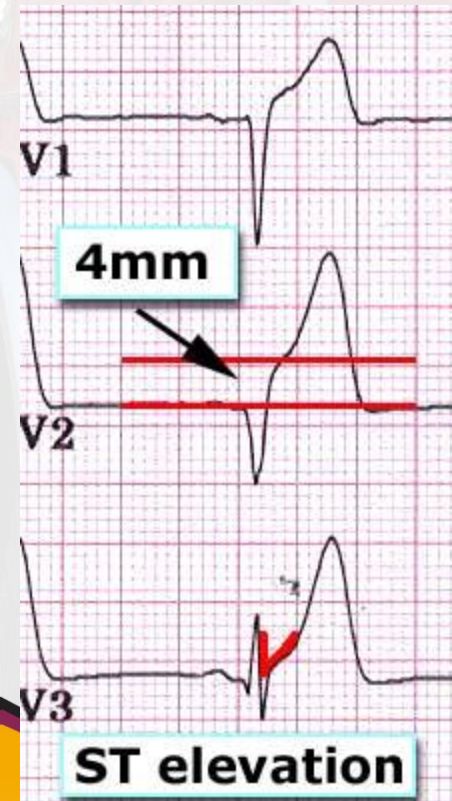
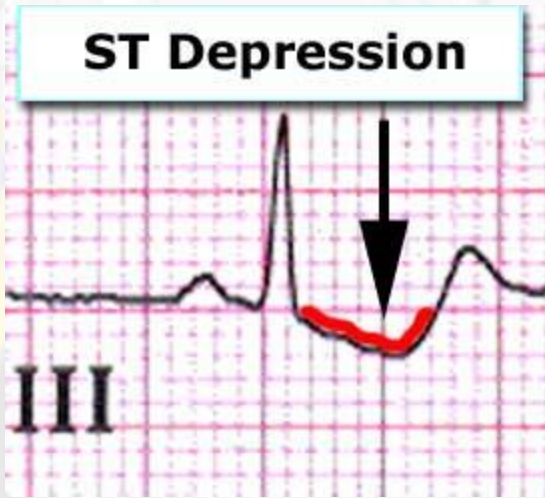
P-R-T axes 70 71 34





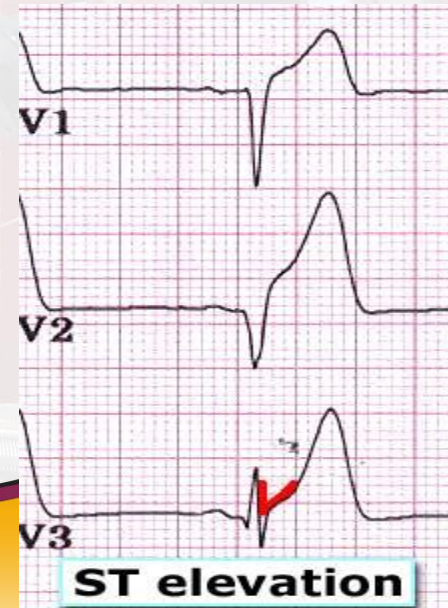
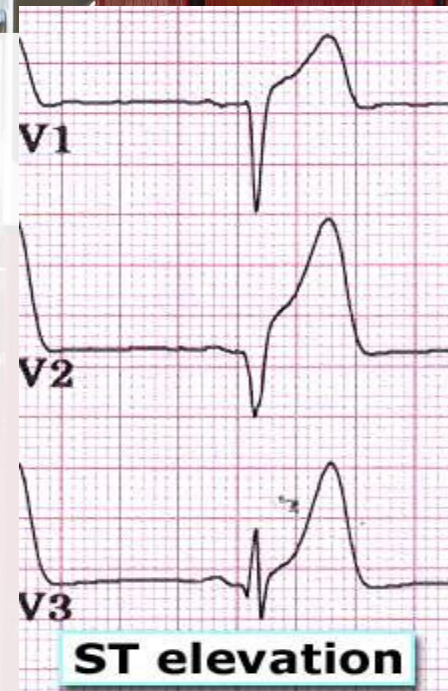
# ST depression and elevation

**ST elevation** in a pattern such as seen in this ECG is called acute subepicardial injury. When there is both **ST segment elevation** and **ST-segment depression** in the same tracing, look to the leads with elevation for the primary anatomic location of injury. This is true even if the **ST depression** appears more obvious than the elevation (compare lead III in this ECG with V3, for example). The **ST depression** seen in the inferior leads is the reciprocal change that typically appears over the wall opposite the injury site.



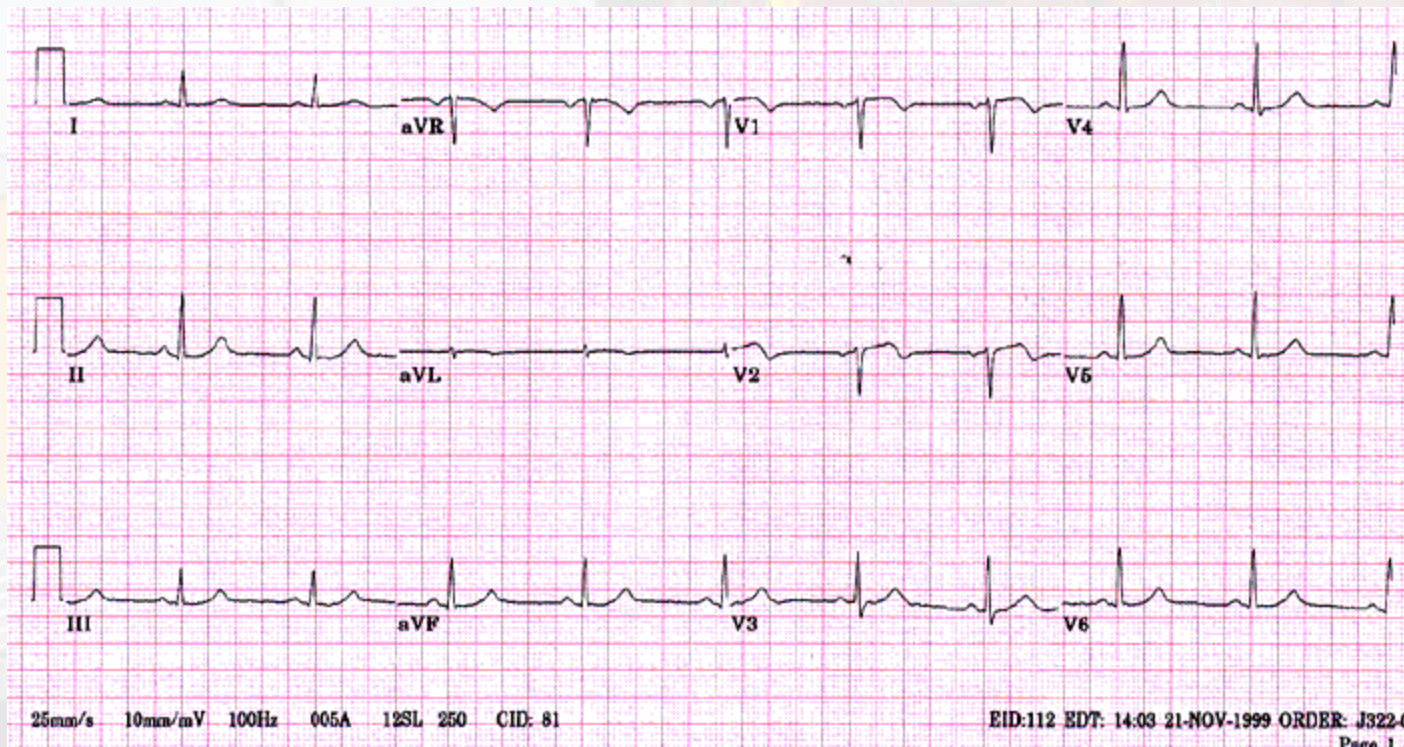
Injury is the term used in electrocardiography for the "current of injury," manifested as **ST-elevation**. Infarction is inferred when there is ECG evidence of necrosis; i.e., when pathologic q-waves develop. Look at leads V1 through V3. There is a tiny r-wave that precedes the S in V1 (this is normal). There is no r-wave in V2 and hence we call this a QS complex (in V2, this is abnormal). The embryonic q-wave in V3 is also abnormal indicating early necrosis also.

The red V-shape drawn between the QRS and the ST-segment in V3 is to highlight a shape we think implies that this man's injury is very acute, an excellent opportunity for intervention.

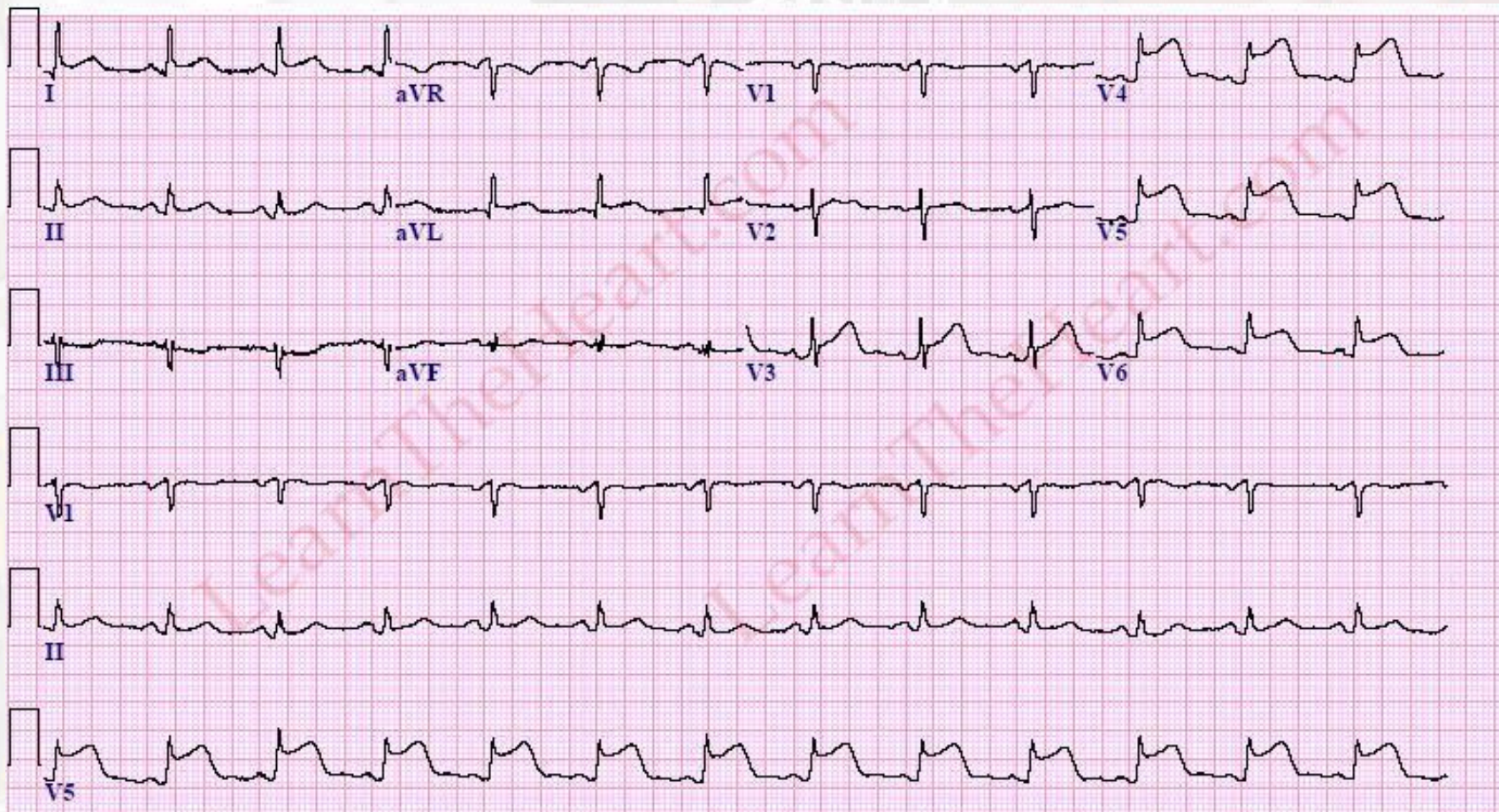




Indeed, this patient immediately received thrombolytics and the ECG taken 70 minutes later (chest pain free) showed resolution of the injury pattern and the q-waves had disappeared.







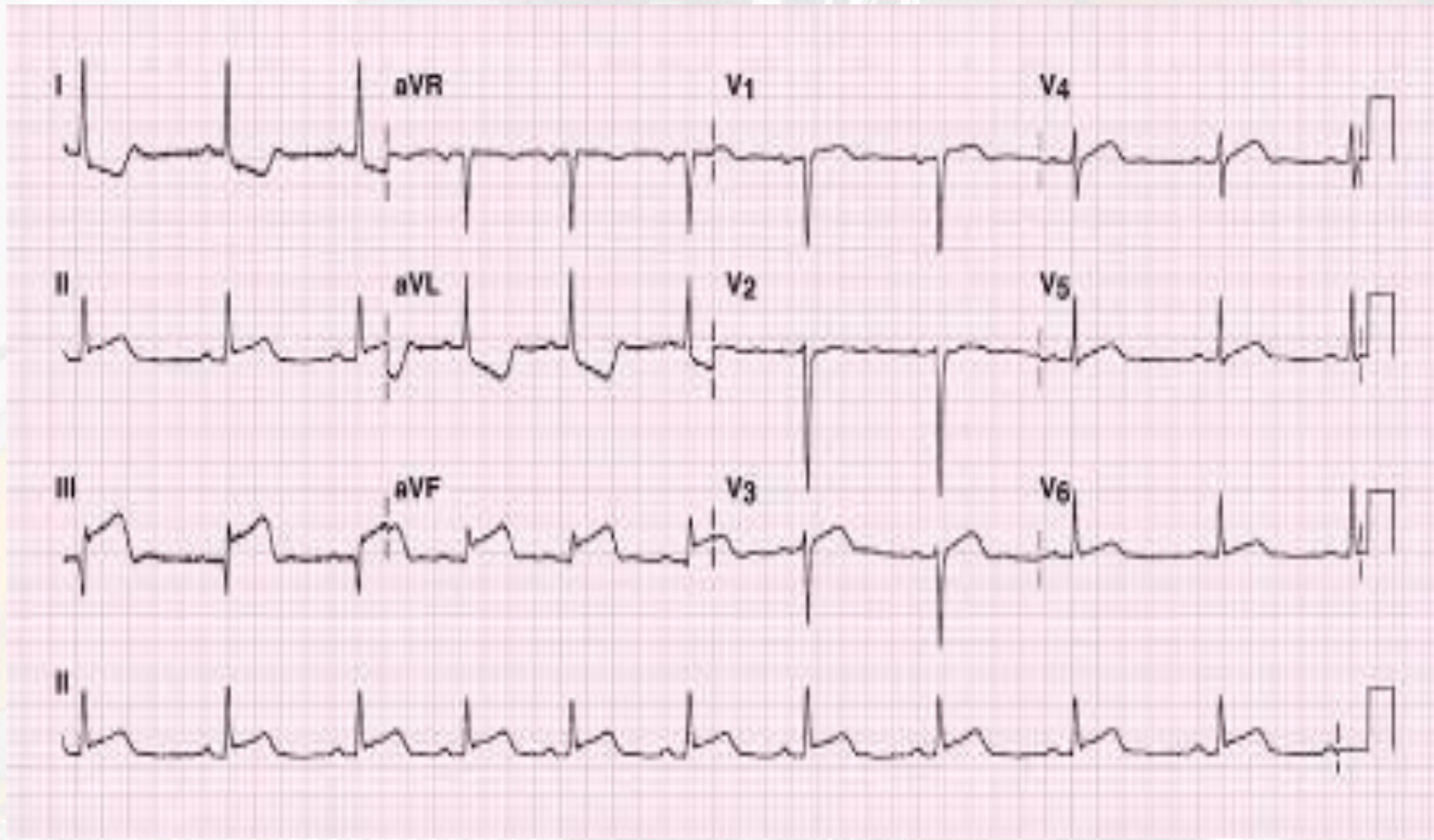
25mm/s 10mm/mV 150Hz 005C 12SL 250 CID: 1

EID:688 EDT: 11:05 16-MAR-2004 ORDER:



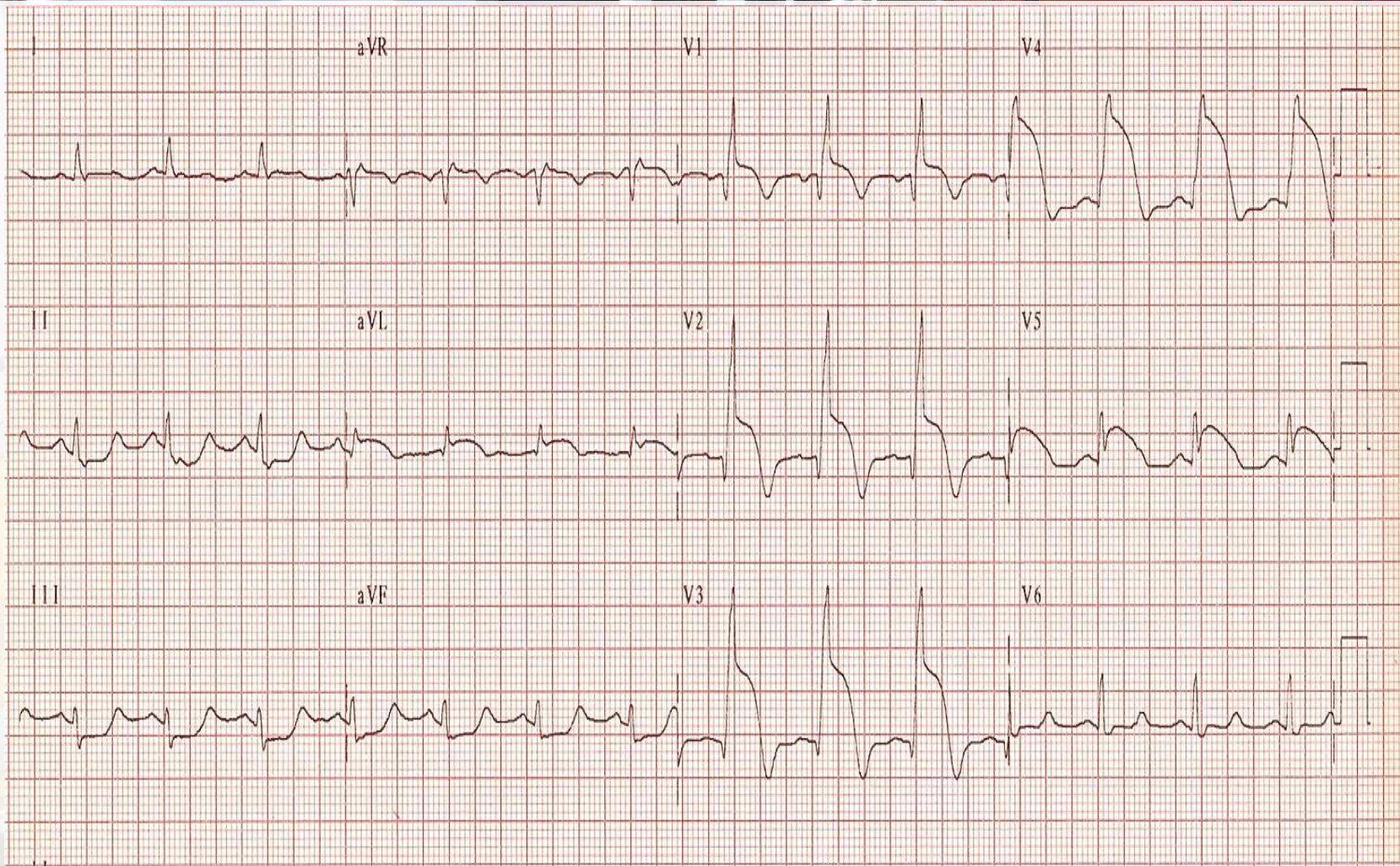
Eastern Idaho  
**REGIONAL**  
MEDICAL CENTER





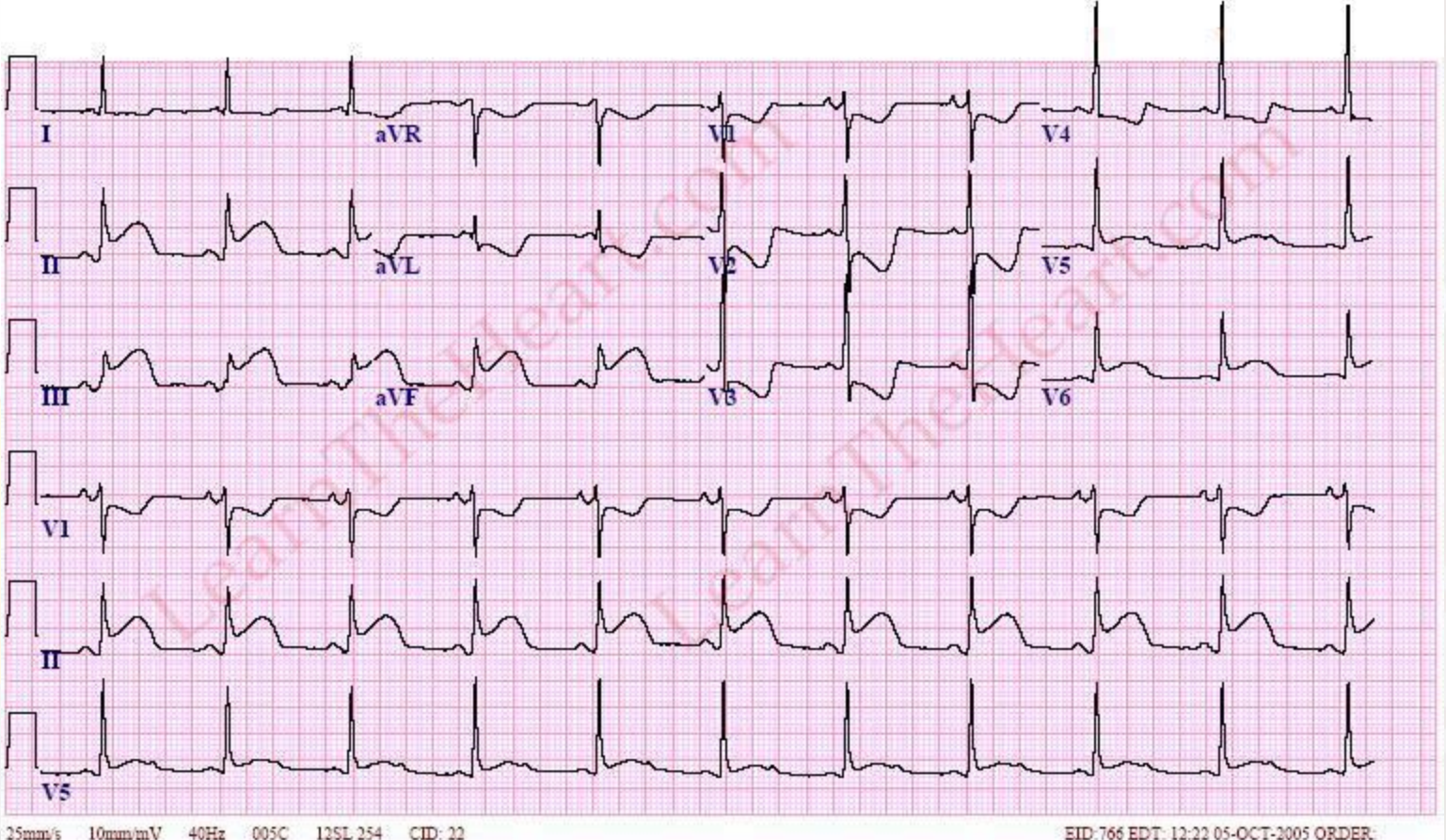
*Eastern Idaho*  
**REGIONAL**  
MEDICAL CENTER





*Eastern Idaho*  
**REGIONAL**  
MEDICAL CENTER





# Thanks!

